

Fascioliasis

A Case Presentation

Dr. kourosh Mojtahedi
Gastrointestinal & Liver Diseases Research Center
Guilan University of Medical Sciences
GLDRC. GUMS

Case Presentation

- A 35-yearold woman presented to the office with complaints of intermittent episodes of dull-aching sensation over the right upper abdomen for 2 weeks.
- This was not associated with jaundice, vomiting, fever, or abdominal distention.

- She was afebrile, hemodynamically stable, comfortable, and clinically anicteric.
- An abdominal examination revealed mild tenderness over the right hypochondrium without palpable organomegaly.

- The rest of the systemic examination was unremarkable. Her hemogram revealed a total leukocyte count of 10,760 cells/mm3 , a differential count of neutrophils 33%, lymphocytes 44%, monocytes 3%, and **eosinophilia (20%)**. Her liver function tests, serum tumor markers, and stool microscopic examination were all within normal limits.

An abdominal ultrasonogram (USG) showed **a** **serpiginous hypoechoic** **structure** in **segment II** of the **liver** with **central hyper-echogenicity** surrounding the liver parenchyma,, as shown in Figure 1.

A serpiginous Hypoechoic Structure

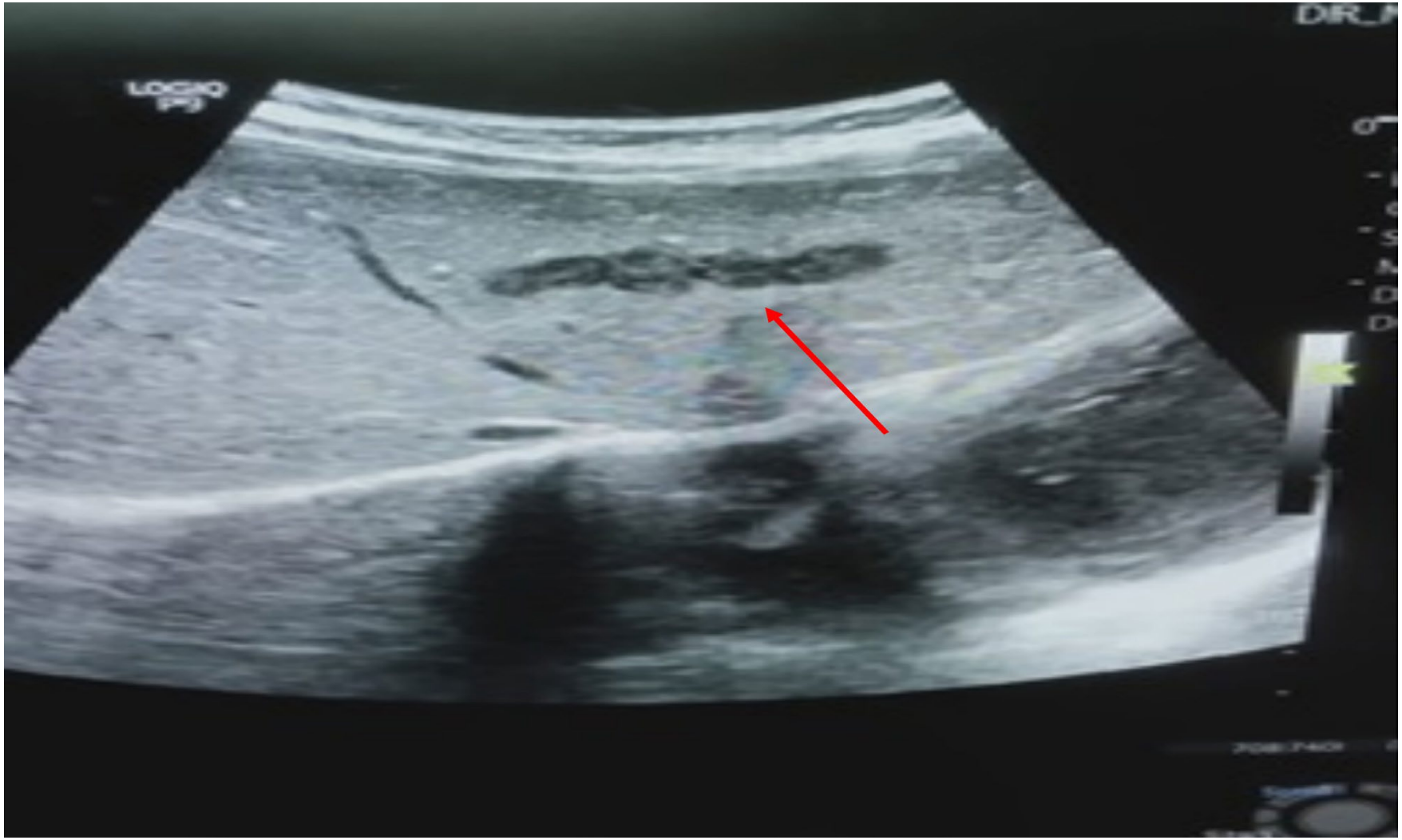

The contrast-enhanced abdominal MRI revealed Figure 2.

A tubular Area with peripheral mild to moderate enhancement

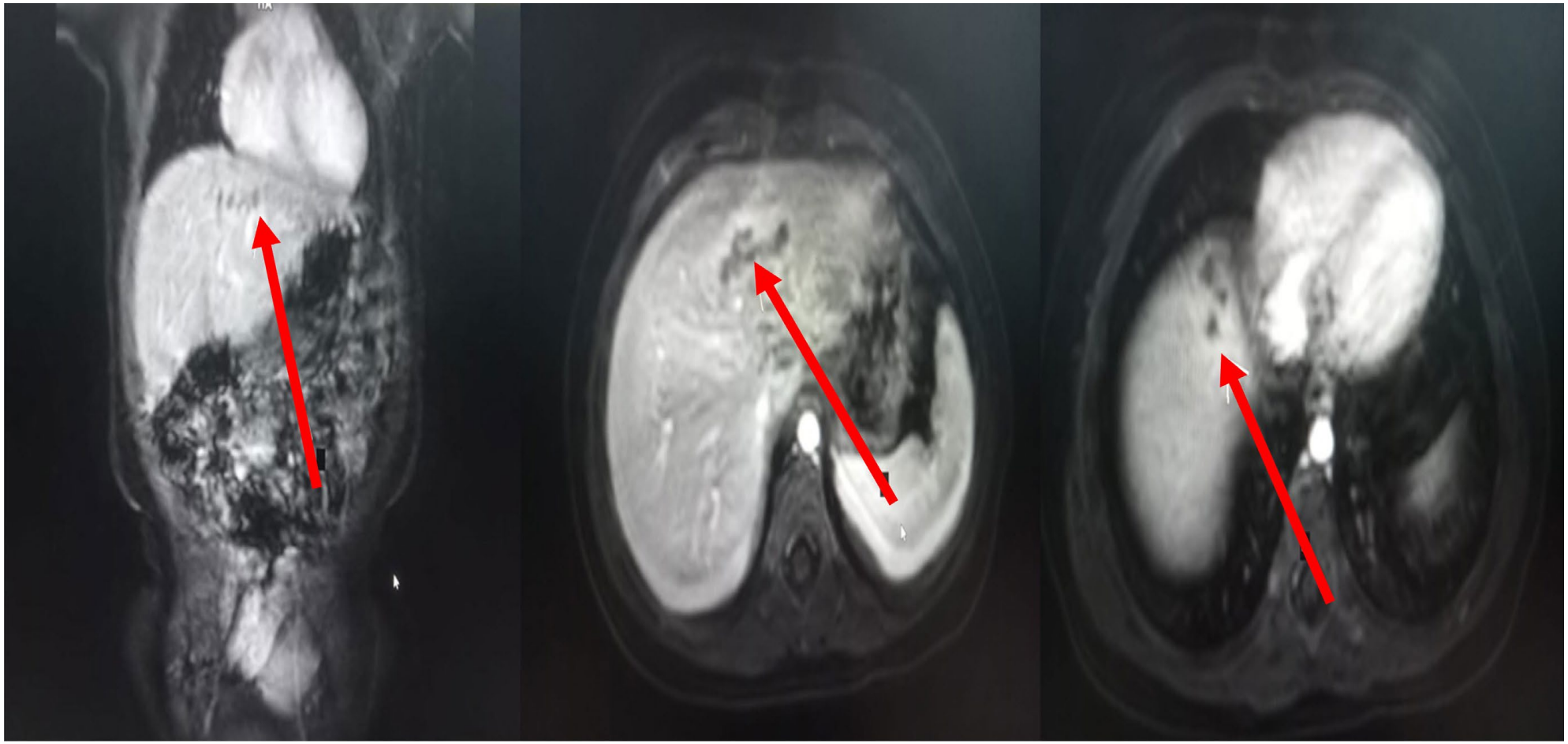

Many other disease presenting with similar image findings can be taken into consideration

Nonetheless, **Fascioliasis** should always be suspected when there are **Numerous Confluent Non-enhancing Hypodense lesions** aligned within **a tract** next to **the liver capsule**.

Biopsy of these lesions may reveal Eosinophilic infiltration,coagulation necrosis, or microabscesses, none of which are of specific diagnostic value

Due to the possibility of **inadequate Yield**, a lack of specific **Pathological** findings, and associated **risks**, an invasive procedure like a liver **Biopsy Was Deferred**.

- A single dose of 10mg/kg **Triclabendazole was started**

At every visit, a clinical examination and an ultrasonological assessment were performed. Gradual **Improvement** was noted symptomatically and radiologically.

A **follow-up** abdominal ultrasound **After Two Months** showed multiple **Hypoechoic Foci** within segment II of the liver that were comparatively **Smaller In Size** without posterior acoustic shadowing, indicating soft calcifications with dormant fascioliasis, as shown in **Figure 3**

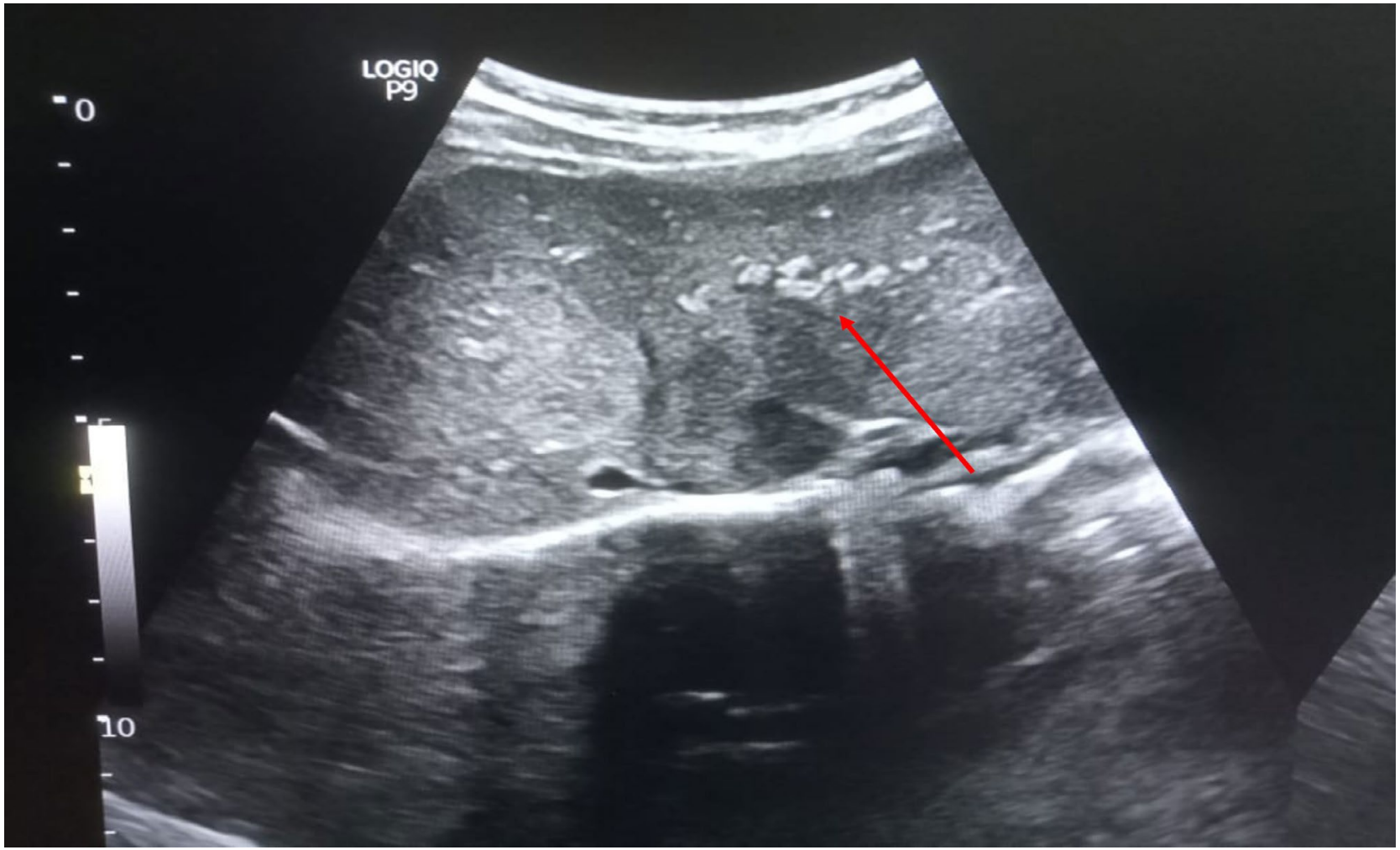
LOGIQ
P9
0
10

A follow-up hemogram showed normal blood eosinophil counts (**2% eosinophils**). At one year's follow-up, she remained **symptom-free**.

Introduction

- Fasciola hepatica (FH) is a leaf-shaped **Trematode** that usually attacks cattle and sheep.

Epidemiology

- The greatest number of infected people has been reported in Bolivia, China, Ecuador, Egypt, France, Iran, Peru, and Portugal

- Humans can become accidental hosts through drinking contaminated water or ingesting **Raw Green Vegetables** contaminated with **Encysted Metacercariae**

- The larva penetrates the intestinal wall to enter the peritoneal cavity.

- It then usually passes through the liver capsule and hepatic tissues where, it becomes an adult, finally invades the biliary tract

clinical phases

- Infestation with FH has two distinct clinical phases: One corresponding to hepatic migratory phase of flukes, and Other corresponding to presence of parasites in their final location in bile ducts.

- FH infestation may be suspected in patients who exhibit tender hepatomegaly, fever, and **Eosinophilia**. Adult flukes can cause **0bstructive Jaundice** or make a patient vulnerable to **Cholelithiasis**

MRCP → ERCP

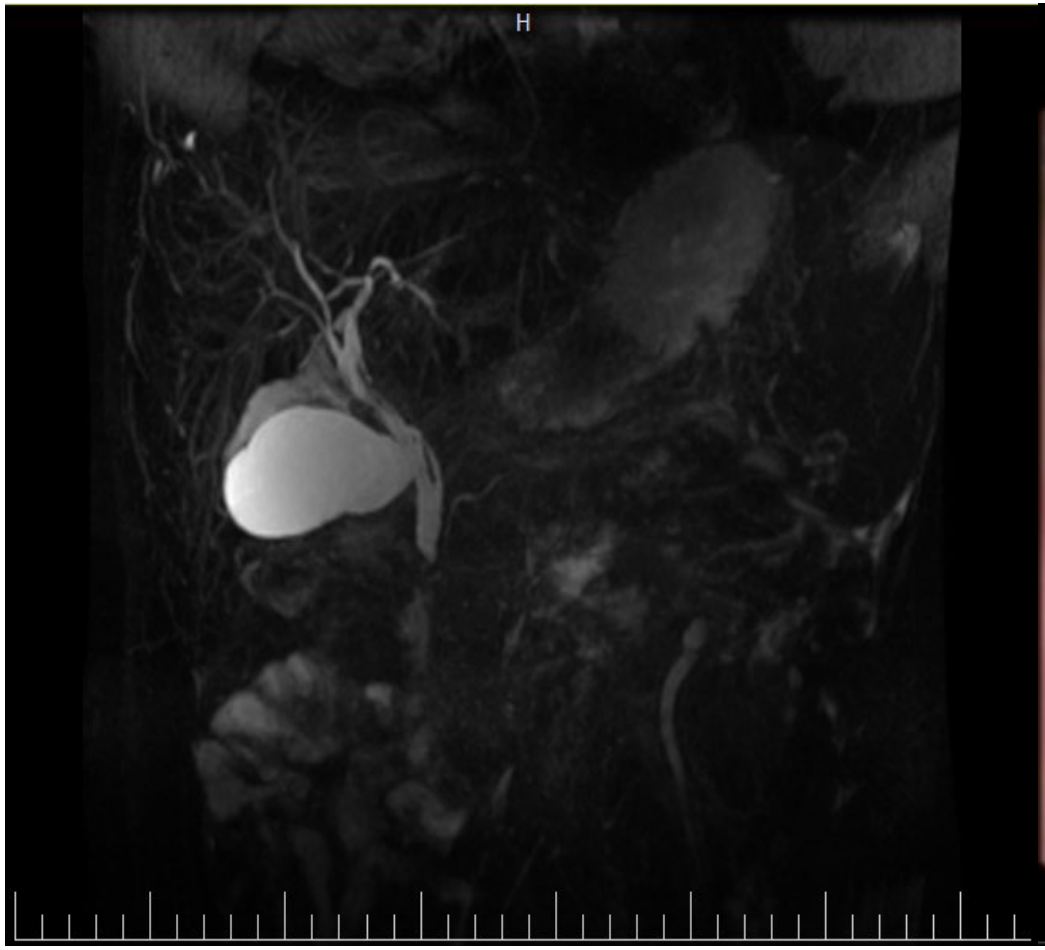



Exraction of parasite

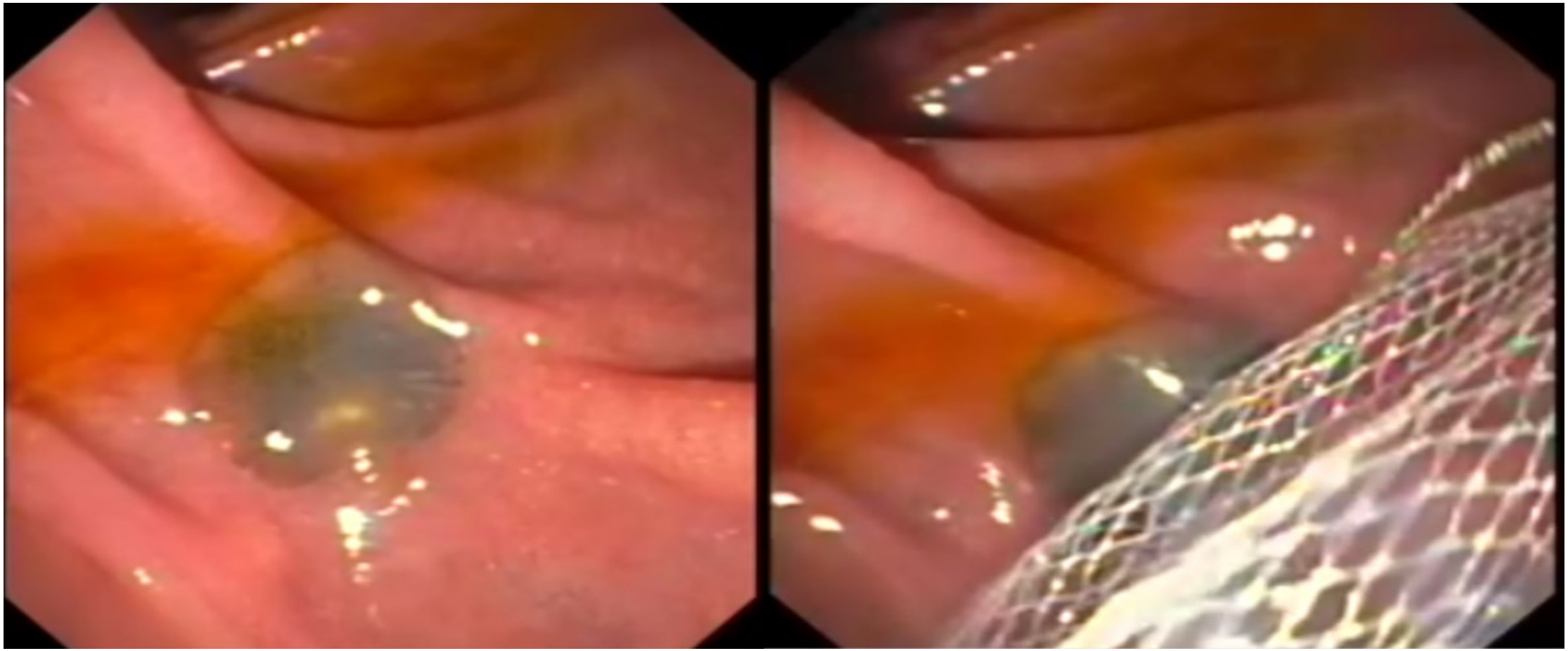

Triclabendazole is an available and **well-tolerated** option for fascioliasis, both in the acute and chronic phases.

A single dose of **10mg/kg or two 5mg/kg doses** are usually effective with a high cure rate.

Triclabendazole Resistance has also been observed globally owing to alteration in the mechanisms of drug uptake, efflux, and detoxification

An alternate drug, **Nitazoxanide**, A **Broad-spectrum Antiparasitic Agent** with minimal adverse effects, is seen to be equally effective and well tolerated

Strongyloides stercoralis (*S.stercoralis*)

A Case Presentation

Introduction

- **S***trongyloides stercoralis* (*S. stercoralis*) is an intestinal **Nematode** parasitic infection which frequently occurs in tropical and subtropical countries with **Temperate climates**

Presentation

- ***S. stercoralis*** usually causes **Asymptomatic condition** particularly in immunocompetent individuals and remain unnoticed even for decades

- **Strongyloidiasis found More Severe in patients who are Immunocompromised particularly those on Corticosteroids use and may be associated with high mortality**

- There are two forms of complicated strongyloides infections including **Hyperinfection syndrome** and **Disseminated** strongyloidiasis.

Hyperinfection syndrome

- **Hyperinfection syndrome** is defined as an amplification of the normal life cycle of *S. stercoralis* ,***W*ithout** the spread of larvae **Outside** of the usual migration pattern for instance gastrointestinal tract and lungs

Disseminated disease

- **Disseminated disease** is defined by the presence of parasites out-side of the traditional life cycle (in organs other than the skin, GI tract, or lungs) and this form carries a **Mortality** rate of approximately **90%** .

Risk factors of disseminated strongyloidiasis

- (1) Immune deficiency, (2) Hematologic malignancy, (3) Steroids administration(4) HTLV-1 infection, (5) Chronic alcoholism, (6) Renal failure, (7) Transplantation

Diagnosis

- Diagnosis of *S. stercoralis* infection mainly depends on **Serology** and rarely **Tissue samples** are taken for histological evaluation

- **50%-70%** of **Stool examinations** turn to be **Negative** due to difficulty for female *S. stercoralis* to shed their eggs into the intestine

Case presentation

- A 56-year old male who presented with a Nine months history of episodes of Fever, Abdominal pain, Nausea, Loss of appetite, and diarrhea which was associated with mucus a traces of blood.

- The nature of abdominal pain was described as **Epigastric**, sharp and **non-radiating**, which would worsen after eating, and not relieved by defecation.

- The patient had **uneventful** past medical and family history. Either he had no known history of drug reaction and any relevant genetic information or smoking.

- History of using steroids, HIV , and **HTLV-1 tests** also were negative.

Physical examination

- He was slightly wasted (**body weight 51 kg**) and pale with normal vital signs. His abdomen was **soft** but **Markedly tender** on percussion around the epigastrium region. Neither free fluid nor organomegaly was found. His DRE was unremarkable, and all other systems were unremarkable.

- CBC showed anemia level of **HB 10 g/dl** and normal WBC with **Severe Eosinophilia (5600 × 103 /mm).** Urinalysis did not show any evidence of **UTI** . Acute abdominal series was obtained and showed **no evidence of obstruction or perforation**.

- Endoscopy revealed **Erythematous**, **Hypertrophied**, and **Ulcerating lining mucosa** **of the duodenum** from which endoscopic tissue biopsies were taken
- The specimen sampled showed sections of the duodenum with numerous ***S stercoralis*** **larvae**, some inside the crypts with associated active duodenitis

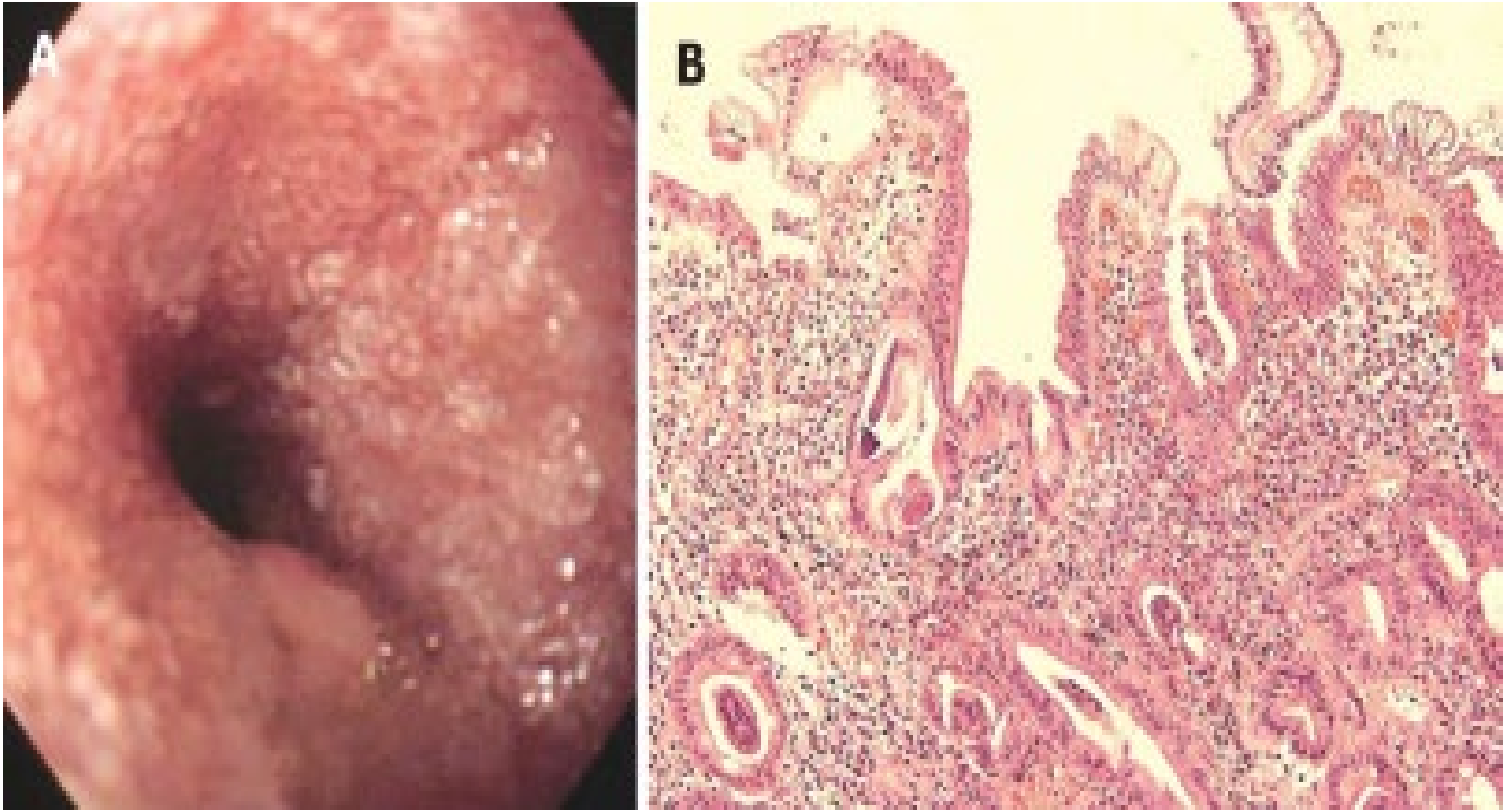
A
B

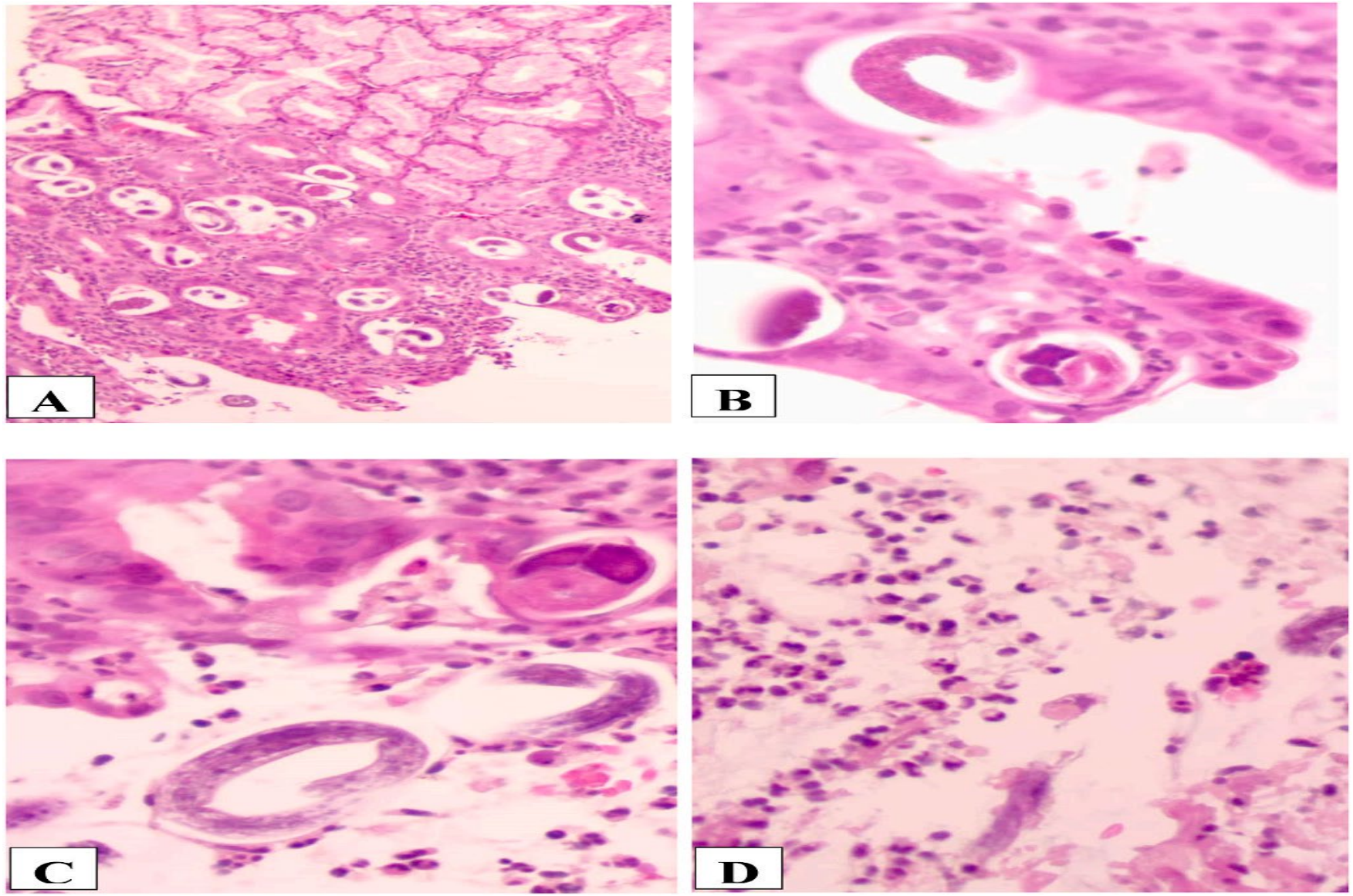
A
B
C
D

- As patient weighed 51 kg, he was started on **Oral course** of **Ivermectin 9 mg** daily until his symptoms of fever, abdominal pain, nausea, vomiting and diarrhea resolved. The patient received ivermectin for a **total of 14 days**.

- **Two months later**, he was evaluated for possible reoccurrence of the symptoms, however, he was found **to have none**.
- Furthermore, microscopic examination of stool and detection of strongyloides IgG antibodies were performed during follow-up which were **both negative** for larvae and larval antigen, respectively

